

CASE REPORT / PRACA KAZUISTYCZNA

Anna Bienkowska¹, Marek Jedwabiński¹, Dariusz Mątewski¹, Katarzyna Janowiak - Maciejewska^{1,2}, Katarzyna Pilecka - Rybka^{1,2}

**RETROPERITONEAL HEMATOMA AFTER USE OF ORAL ANTICOAGULANTS IN THE POSTOPERATIVE PERIOD COMPLICATED BY ATRIAL FIBRILLATION
- A CASE REPORT.**

**KRWIAK ZAOTRZEWNOWY PO ZASTOSOWANIU DOUSTYNYCH ANTYKOAGULANTÓW W OKRESIE POOPERACYJNYM POWIKŁANYM MIGOTANIEM PRZEDSIONKÓW
- OPIS PRZYPADKU**

1. Department of Orthopedics and Traumatology with Unit of Early Rehabilitation in Orthopedic Diseases and Injuries, Ludwik Rydygier College of Medicine in Bydgoszcz, Nicolaus Copernicus University in Torun.
Acting Head: Marek Jedwabiński, PhD
2. Chair and Department of Kinesiotherapy and Therapeutic Massage, Medical University in Bydgoszcz, Ludwik Rydygier College of Medicine in Bydgoszcz, Nicolaus Copernicus University in Torun

Summary

One of the elements of therapeutic conduct aimed at avoiding the most severe cardiovascular events such as: heart attack or brain ischemic stroke is the treatment against thrombosis with the use of low molecular weight heparin, anticoagulants and anti – platelet drugs. This therapy is related with bleeding complications, occurring 2 -20% of the patients during treatment with anticoagulants.

The aim of this study is to analyze the complications of anticoagulation with oral anticoagulants and low molecular weight heparin in the treatment of cardiac event in the early postoperative period after total hip replacement

In 5 day after right THA an event of atrial fibrillation (AF) occurred in 69 year old patient. According to cardiologist recommendation oral anticoagulant was administered to accompany previously used low molecular heparin on the 14th day after surgery. At the moment when the therapeutic dose was achieved the patient presented severe pain which

was localized in a right inguinal region and also in a surgically treated hip. The next day it was observed further increase in pain intensity as a right – sided femoral neuralgia accompanied by neurological deficits such as: progressive disorder of sensation on the front surface of the right thigh, weakness right knee reflex muscle, weakness in the active hip flexion and knee extension. In CT and ultrasonography examination the huge retroperitoneal hematoma in a right lumbar-iliac muscle was imaged.

Severe hip pain after total hip replacement with progressive symptoms of peripheral nerve lesion obligated to do additional examination in the field of diagnostic imaging of the abdomen and requires a multidisciplinary evaluation. Taking into consideration indications and contraindications and an extensive clinical and laboratory monitoring are crucial conditions to prevent bleeding during anticoagulant therapy.

Streszczenie

Jednym z elementów postępowania terapeutycznego mającym zapobiec najcięższym incydentom sercowo-naczyniowym, takim jak zawał serca lub udar niedokrwienny mózgu jest leczenie przeciw zakrzepowe. Leczenie to wiąże się jednak z ryzykiem powikłań krwotocznych, występujących u 2-20% chorych w czasie leczenia antykoagulantami. Celem pracy jest analiza powikłania leczenia przeciw zakrzepowego

z zastosowaniem doustnych antykoagulantów i heparyny drobnocząsteczkowej w terapii incydentu sercowego we wczesnym okresie pooperacyjnym po endoprotezoplastyce stawu biodrowego.

U chorej lat 69 po incydencie migotania przedsionków w 5 dobie pooperacyjnej, od 14 doby rozpoczęto leczenie p/ zakrzepowe z wykorzystaniem heparyny drobnocząsteczkowej

i antykoagulantów doustnych. W momencie uzyskania dawki terapeutycznej chora zgłosiła silne dolegliwości bólowe zlokalizowane w okolicy prawej pachwiny i operowanego stawu biodrowego. W kolejnym dniu obserwowano dalsze narastanie natężenia bólu o charakterze rwy udowej prawostronnej z towarzyszącymi deficytami neurologicznymi: postępującym zaburzeniem czucia na przedniej powierzchni uda prawego, osłabieniem odruchu kolanowego prawego, osłabieniem siły mięśniowej w zakresie czynnego zgięcia stawu biodrowego i wyprostu stawu kolanowego. W wykonanych badaniach TK i USG stwierdzono duży krwiak zaotrzewnowy prawego dołu biodrowego.

Key words: antithrombotic therapy, total hip arthroplasty, anticoagulants, retroperitoneal hematoma, femoral neuralgia.

Słowa kluczowe: leczenie p/zakrzepowe, endoprotezoplastyka, antykoagulanty, krwiak zaotrzewnowy, rwa udowa.

ADMISSION

Europe's maximum total is approximately 490 million inhabitants and it is performed every year about 7 million major surgery. Among the many potential postoperative complications there are cardiovascular diseases, which are the most important. The large operations incidence of cardiac deaths is 0.5 – 1.5% and non – fatal cardiac complications is 2.0 – 3.0% [1]. The risk of cardiovascular complications during major surgery is associated with a large incidence of cardiovascular diseases, which still have the first cause of death in Europe. This confirms the nature of the disease of civilization. Development and implementation of new ways of conduct therapeutic aim is to reduce the wear indicator. One of the elements of therapeutic conduct aimed at avoiding the most severe cardiovascular events such as: heart attack or brain ischemic stroke, is the treatment against thrombosis with the use of low molecular weight heparin, anticoagulants and anti – platelet drugs [2].

It also has its implications for the surgical specialties as increases the risk of perioperative bleeding. Even without surgery anticoagulation is related with bleeding complications, occurring 2 – 20% of the patients during treatment with anticoagulants and mortality averages is about 0.3% (0.01 – 1.5%) [3].

The aim of this study is to analyze the complications of anticoagulation with oral anticoagulants and low molecular weight heparin in the treatment of cardiac event in the early postoperative period after total hip replacement.

A CASE REPORT

A 69-year old patient, admitted to the Orthopedic Clinic of the University Hospital number 1 in Bydgoszcz, to a planned total arthroplasty of the hip. The acceptance complained of ill not from cardio – vascular. Because of the recognized hypertension she was pharmacologically treated. Perioperative prophylaxis standard applied with the use of low molecular weight heparin. In 5 days after operation of typical incident occurred, and it was retrosternal pain during an attack of atrial fibrillation (AF). The recommended angiography, performed by the cardiologist of the radial artery showed no changes in the coronary vessels. Due to paroxysmal atrial fibrillation and scores on a scale CHA₂DS₂-VASc=3 recommends the need to include oral anticoagulant. Because

Silny ból stawu biodrowego w okresie pooperacyjnym po endoprotezoplastyce stawu biodrowego z postępującymi objawami uszkodzenia nerwu obwodowego obliuguje do wykonania badań dodatkowych w zakresie diagnostyki obrazowej jamy brzusznej i przestrzeni zaotrzewnowej oraz wymaga spojrzenia wielospecjalistycznego. Uwzględnienie wskazań i przeciwwskazań oraz dokładna kontrola kliniczna i laboratoryjna są nieodzownymi warunkami zapobiegania krwawienia w czasie leczenia antykoagulantami.

of the early post – operative period was increased at the beginning dose of low molecular weight heparin in therapeutic doses for preventive. The patient was transferred to a Branch of Early Rehabilitation to continue rehabilitation treatment. Within the next two weeks patient breathing exercises used kinesitherapy: active exercises in relieving lower limbs, active in relieving exercises with resistance exercises of the upper limb, proprioception exercises of motor control the body. The patient was independent and well – tolerated treatment. She moved with the help of two elbow crutches. On the 14th day after surgery that used heparin subcutaneously accompanied by oral anticoagulant.

At the moment of the therapeutic dose a female presented severe pain which was localized around the right a female presented severe pain hip surgical. A clinical examination and radiological excluded sprain right hip replacement as well as other causes associated with implant. Initially enrolled analgesic drugs called NSAIDs. No improvement has forced the use of Tramadol, which first brought not – satisfying results and then Dolargan analgesic dose of 200mg/24 hours of relatively good analgesic effect. They take a picture of X – ray lumbar spine on which the radiologist stayed a completed circle L1 compression fracture and evidence of disc herniation. The next day it was observed further increase in pain intensity as a right – sided sciatic femoral accompanied by neurological deficits such as: progressive disorder of sensation on the front surface of the right thigh, weakness right knee reflex muscle weakness in the active hip flexion and knee extension.

We asked about neurosurgical consultation for suspected disc herniation paralytic L3 and L4. Commissioned by the neurosurgeon, performed a CT Scan of the L-S spine, in which revealed growing, old healed fracture of the L1 and multi – core discopathies – clinically irrelevant. Simultaneously, at the level of the iliac crest revealed a hematoma, the size of 80 to 55 mm in the retroperitoneal space on the right hip in the muscle of the characteristic of bleeding into the kidneys space (at the right side) and bleeding to the pelvic fat tissue (Figure 1). This image was correlated with clinical symptoms presented by the patient. Abdominal ultrasound was performed which confirmed the retroperitoneal hematoma right iliac and said there is no fluid in the peritoneal cavity (Figure 2). Morphology parameters did not show acute bleeding. Anticoagulant therapy was stopped to normalize blood clotting parameters. In made angio – CT of the abdomen showed no extravasation of contrast outside the lumen of blood. Due

to a decrease in pain intensity, there were no signs of active bleeding and the risk of further complications; it was decided to continue conservative treatment.

In addition, angio – CT in the right kidney were changing the diameter of 16 mm. Urological consultation excluded relationship changes in the kidney with retroperitoneal bleeding.

Within the following 20 days of treatment, the patient experienced relief of pain on the right hip, active bends right hip and right knee extension in relieving, reduced disturbances of sensation in the right femoral nerve innervations, normalization of coagulation parameters and morphology. Functional status at discharge: patient would sit alone; she could walk with the aid of elbow crutches on short distance with the assistance of the therapist.

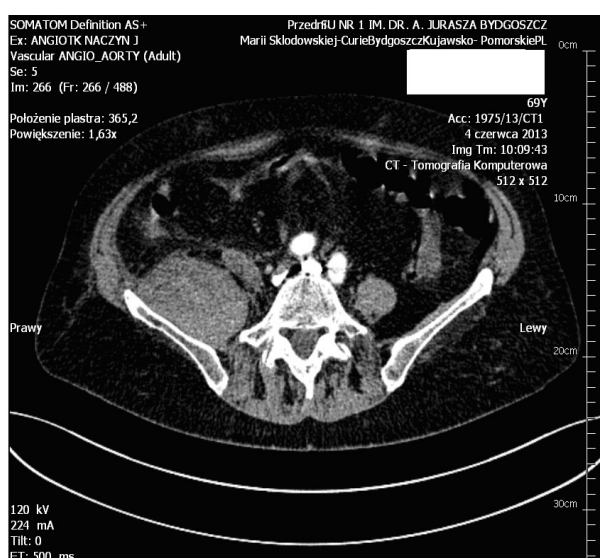

Figure 1.

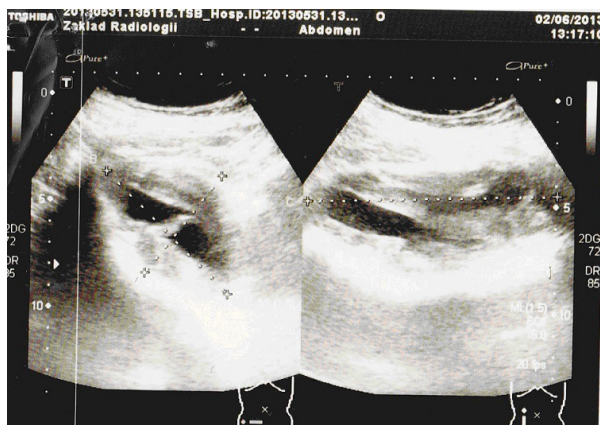


Figure 2.

DISCUSSION

Atrial fibrillation occurs in the 1 – 2% general population and there is five – time more risks of stroke. Ischemic stroke associated with atrial fibrillation often ends in death and patients who survive them will experience a greater degree of disability. Incidence of AF in the perioperative period increases the risk of serious cardiovascular complications,

because of risk of bleeding, because of a big does not allow the use of anticoagulation in therapeutic doses. Cardiology in the literature is just total of anticoagulation with rate control, and appropriate treatment of conditions is a key factor in preventing morbidity associated with atrial fibrillation [4,5,6].

During anticoagulant therapy the risk of bleeding increases significantly, when the prolongation of the prothrombin time in patients than 4 times the value of the standard formulation (prothrombin pointer below 30%, INR above 5.0). The most common places of bleeding events during treatment with heparin are: bleeding into the intestines intramural hematoma retroperitoneal haemorrhage into the adrenal hematoma pleural and spontaneous splenic rupture.

During treatment with oral anticoagulants the following may occur: haemorrhages central nervous system and retina, hematuria, gastrointestinal bleeding, haemopericardium of cardiac, tamponed bleeding into joint cavities, skin necrosis, bleeding into the adrenal glands and muscle hematomas. Bleeding most likely occur in the place of organic changes in organs [3,7,8].

During anticoagulant therapy the doctor should keep in mind the factors of changing sensitivity in elderly on anticoagulants. In the elderly, often associated several diseases and they must take a variety of medications that can affect the stability of INR and increase the risk of bleeding. It is important to have a closer monitoring of anticoagulation to INR values were located as long as possible in the therapeutic range [2, 6, 9].

CONCLUSIONS

1. Preventing morbidity associated with AF manifested by anticoagulation is related with risk of bleeding.
2. Severe hip pain after total hip replacement with progressive symptoms of peripheral nerve damage obligated to do additional research in the field of diagnostic imaging of the abdomen and requires a multidisciplinary perspective.
3. Taking into consideration, indications and contraindications and an extensive clinical and laboratory monitoring are indispensable condition to prevent bleeding during anticoagulant therapy.

REFERENCES:

1. Hoeks S.E., Poldermans D., Przedoperacyjna ocena ryzyka sercowego i zasady opieki kardiologicznej w okresie okołoperacyjnym u chorych poddawanych operacjom niekardiologicznym. *Medycyna Praktyczna* 2010/08.
2. Hirsh J, Dalen J, Guyatt G; American College of Chest Physicians. The sixth (2000) ACCP guidelines for antithrombotic therapy for prevention and treatment of thrombosis. *American College of Chest Physicians. Chest.* 2001 Jan;119(1 Suppl):1S-2S.
3. Maj S. Polekowe powikłania hematologiczne. *Postępy Nauk Medycznych* 4/2000, s. 17-28.
4. John Camm A., Kirchhof P., Lip G.Y.H. et al. Wtyczne dotyczące postępowania u chorych z migotaniem przedsionków *Kardiologia Polska* 2010; 68, supl. VII: 487–566,

5. John Camm A., Lip G.Y.H, De Caterina R. et al. Wytyczne ESC dotyczące postępowania w migotaniu przedsionków na 2012 rok: Uaktualnienie wytycznych Europejskiego Towarzystwa Kardiologicznego (ESC) dotyczących postępowania w migotaniu przedsionków z 2010 roku, *Kardiologia Polska* 2012; 70, supl. IV: 197–234.
6. Baczyńska A. Doustne leki przeciwkrzepliwe w różnych stanach klinicznych; *Choroby Serca i Naczyn* 2004, 1, (1): 27–36.
7. Windyga J., Powikłania leczenia przeciwkrzepliwego; *Hematologia* 2010, 1 (2): 142–150.
8. Levine M.N., Raskob G., Beyth R.J., et al. Hemorrhagic complications of anticoagulant treatment. *Chest* 2004; 126 (supl. 3): 287S–310S.
9. Łopaciuk S. Leki hamujące krzepnięcie krwi. W: *Zakrzepy i zatory*. PZWL, Warszawa 2002: 125–157.

Address for correspondence:

Szpital Uniwersytecki Nr 1
Klinika Ortopedii i Traumatologii Narządu Ruchu
ul. M. Skłodowskiej-Curie 9, 85-094 Bydgoszcz
Dr n. med. Marek Jedwabiński

Received: 27.05.2013

Accepted for publication: 26.08.2013